

SUBSCRIBE: Print / Digital / eNewsletter

Thread lifts versus surgery

By John Jesitus

Sep 28, 2018

Cosmetic Surgery, Facial Contouring



Thread-lifting techniques have evolved to provide satisfactory short-term results, particularly in the midface, said an expert at The Cosmetic BootCamp. However, he added, thread lifting often works best in conjunction with other procedures such as fat injections and fat contouring. And even at its best, thread lifting cannot approach the results or longevity of specialized surgical results.

Choosing between thread lifts and surgical lifts requires knowing what patients want, and how long they want results to last, said Providence, Rhode Island-based plastic surgeon Patrick Sullivan, M.D. For patients who want to be ready for a near-term event, with little postprocedural downtime, he explained, thread lifts may suffice. But if patients can tolerate a longer recovery in pursuit of more beneficial and durable results, the pendulum swings toward surgery.

After the original non-resorbable barbed sutures became available, said Dr. Sullivan, many patients who had undergone the procedure elsewhere presented at his practice with threads protruding through their skin. Newer resorbable barbed threads are little better, he said. "Those hooks don't seem to do the job as well as some of the other technologies."

The cone-and-suture structure of the Silhouette Instalift (Sinclair) is much more effective, said Dr. Sullivan. In the perioral area, he said, the bidirectional cones seem better able to lift and hold tissue in position. Over time, the polyglactin (glycolide/L-lactin or PGLA) material of which they are made resorbs into the body, forming a temporary filler, as polymethylmethacrylate does.

For perioral lifting, he marks three parallel entry points in the mid-cheek, which correspond to exit points in the upper cheek and perioral area. He then guides a long 18-gauge needle approximately 5 mm under the skin's surface to the upper-cheek exit point.

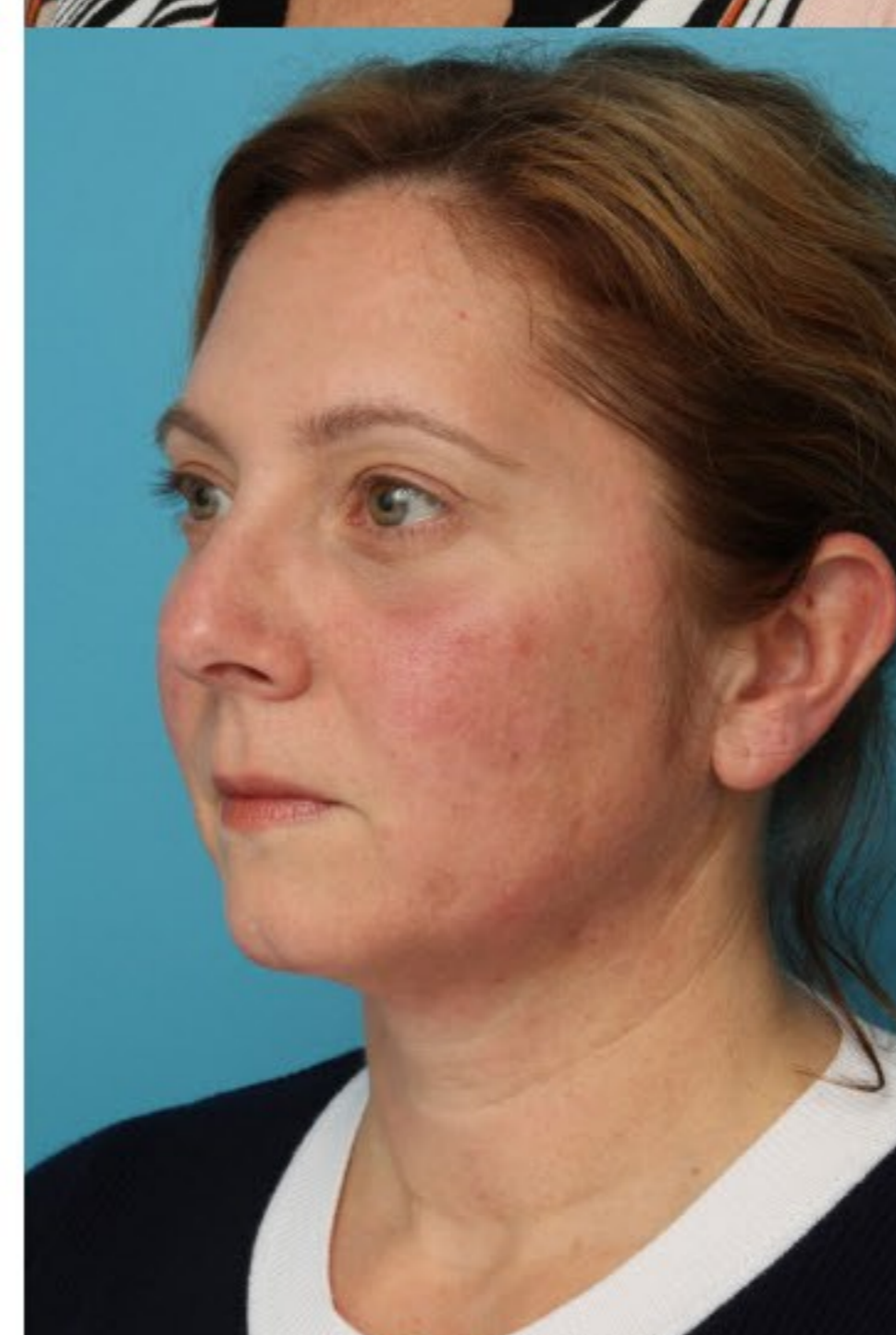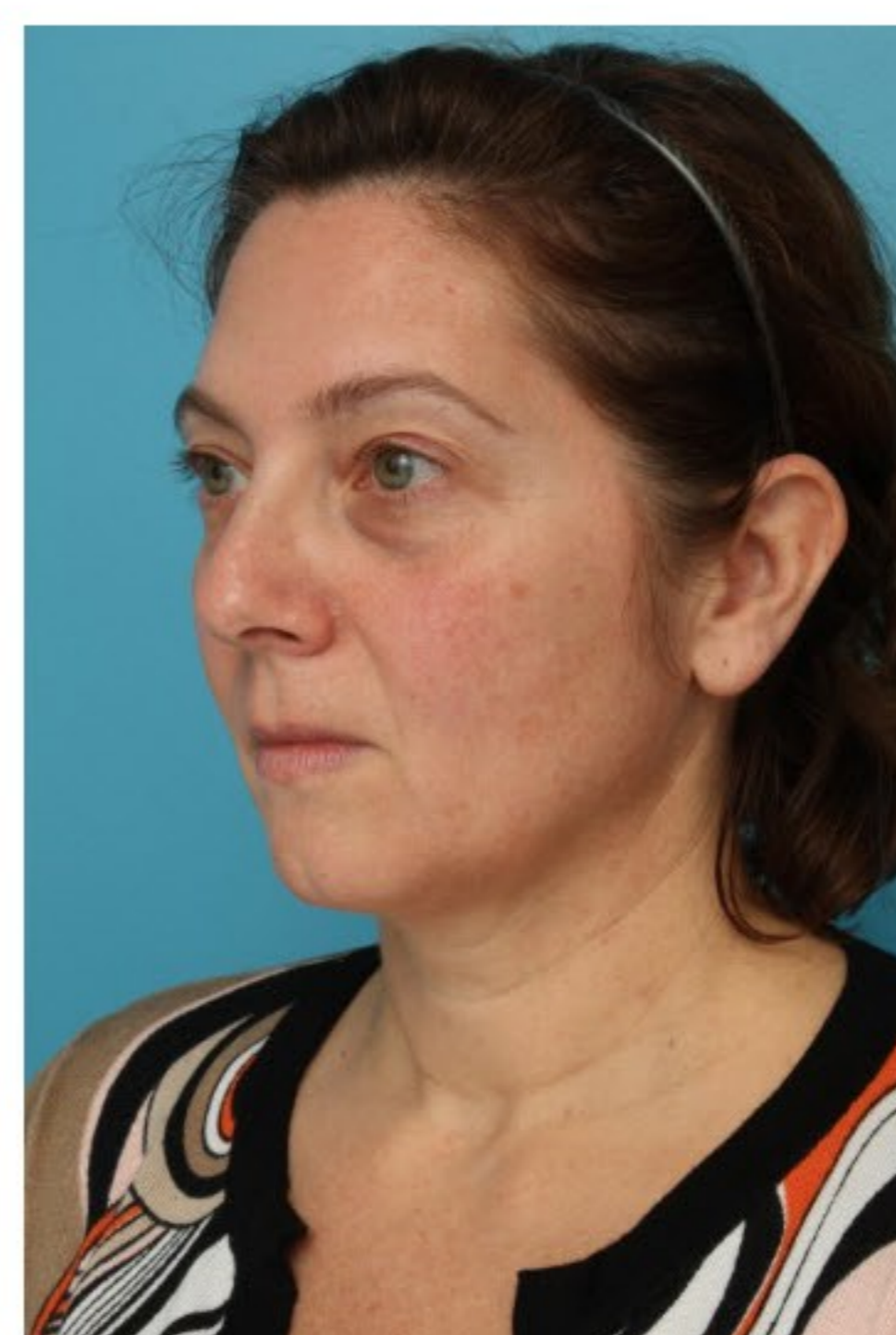
"You can see the different cones being brought through this one entrance site. This opening is not even made with a knife." Then he returns to the central entry point with the other end of the needle and anchors the other end of the suture in the perioral region. "It's very important to feed those cones in perfectly so they don't cause any tethering."

Next, gentle upward pushing across the length of the thread provides medial and lateral lifting as one locks the cones into place. "You can see this lifting, right on the table, which I find very satisfying." Nobody knows how long Instalift results last, said Dr. Sullivan. He advised curbing patients' expectations regarding both duration and the procedure's effect. "The limited results I get are very different from what I get from surgery."

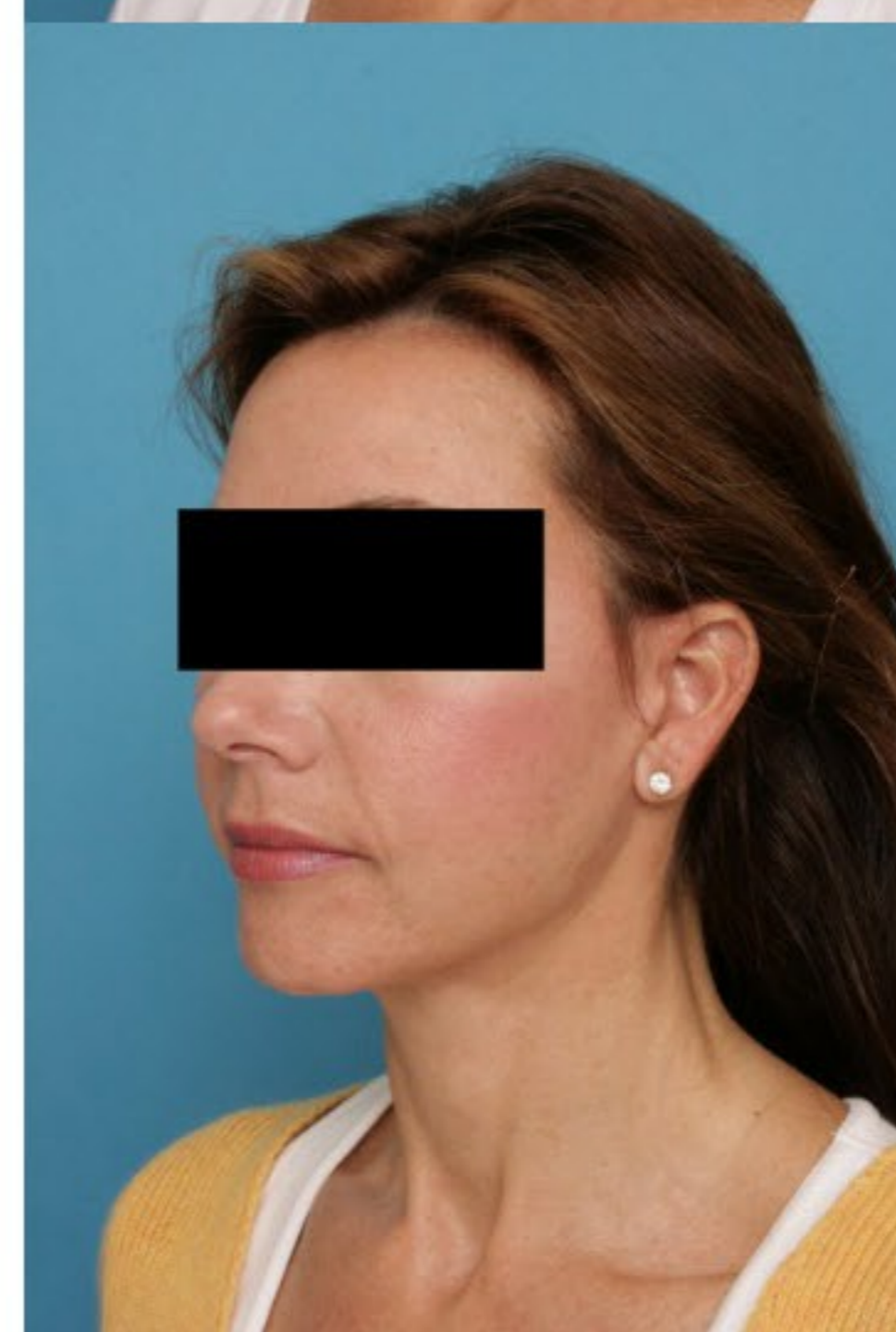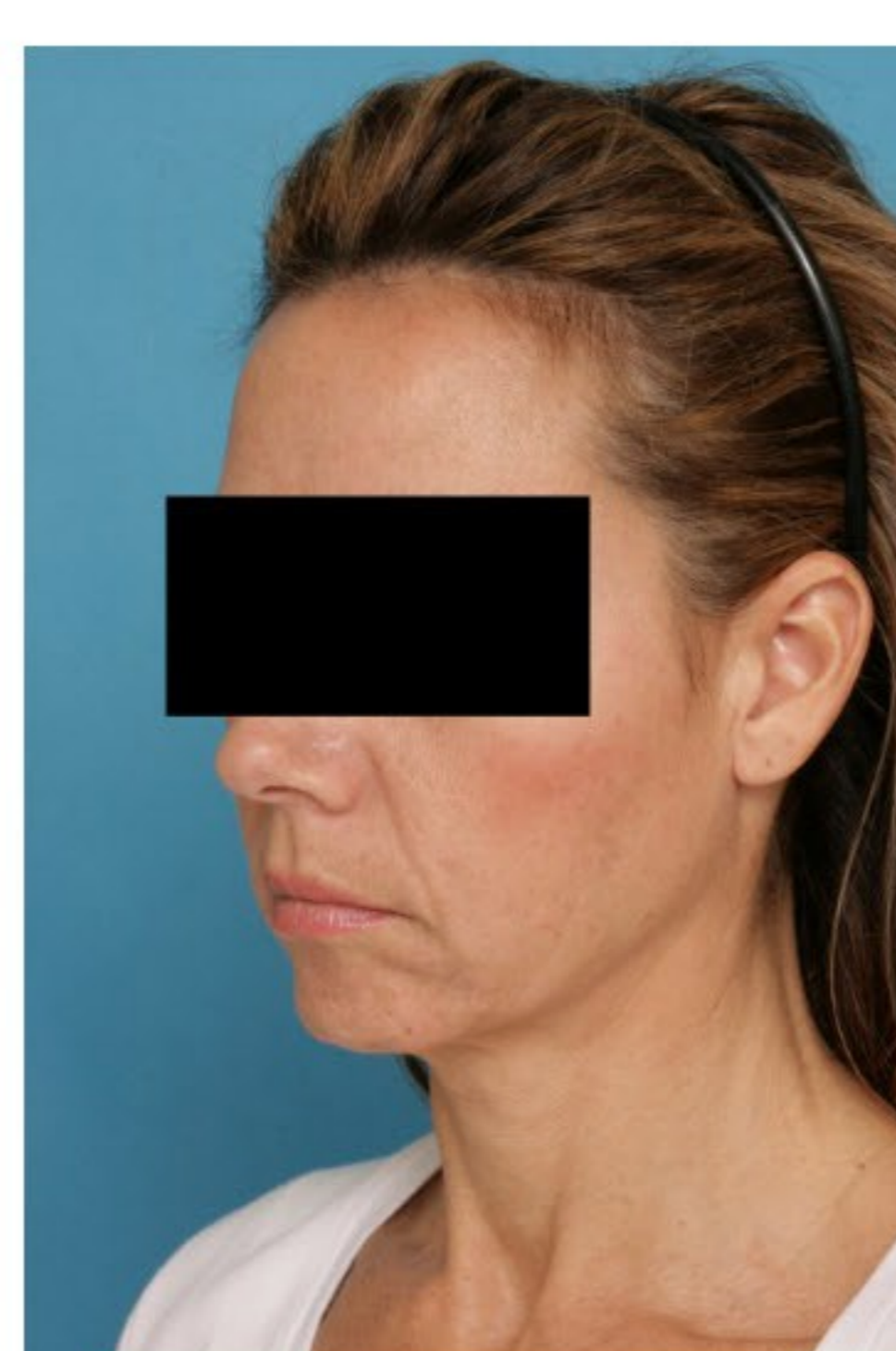Patient selection is critical. One patient he treated underwent surgical blepharoplasty, then decided three days later that her face needed lifting. But she had to return to work the following week. "When you have somebody who wants something extra to better match their upper face, the Instalift is a possibility to consider." For this patient, he said, the procedure provided modest lifting in the perioral area, and with threads along the jawline as well, but nothing in the neck.

"A better candidate might be someone who wants more at the same time." For example, one patient wanted an eyelid lift and fat injections to raise her cheeks and pre-jowl sulcus. "We also removed some fat from the jowl at the same time. When you combine treatments, that's a better approach." For this patient, he first inserted threads extending from the mid-cheek to exit points in the perioral area. "As we mark those out, we can really get a feel for what we want to lift. Then you can create the other exit points back up against the hairline."

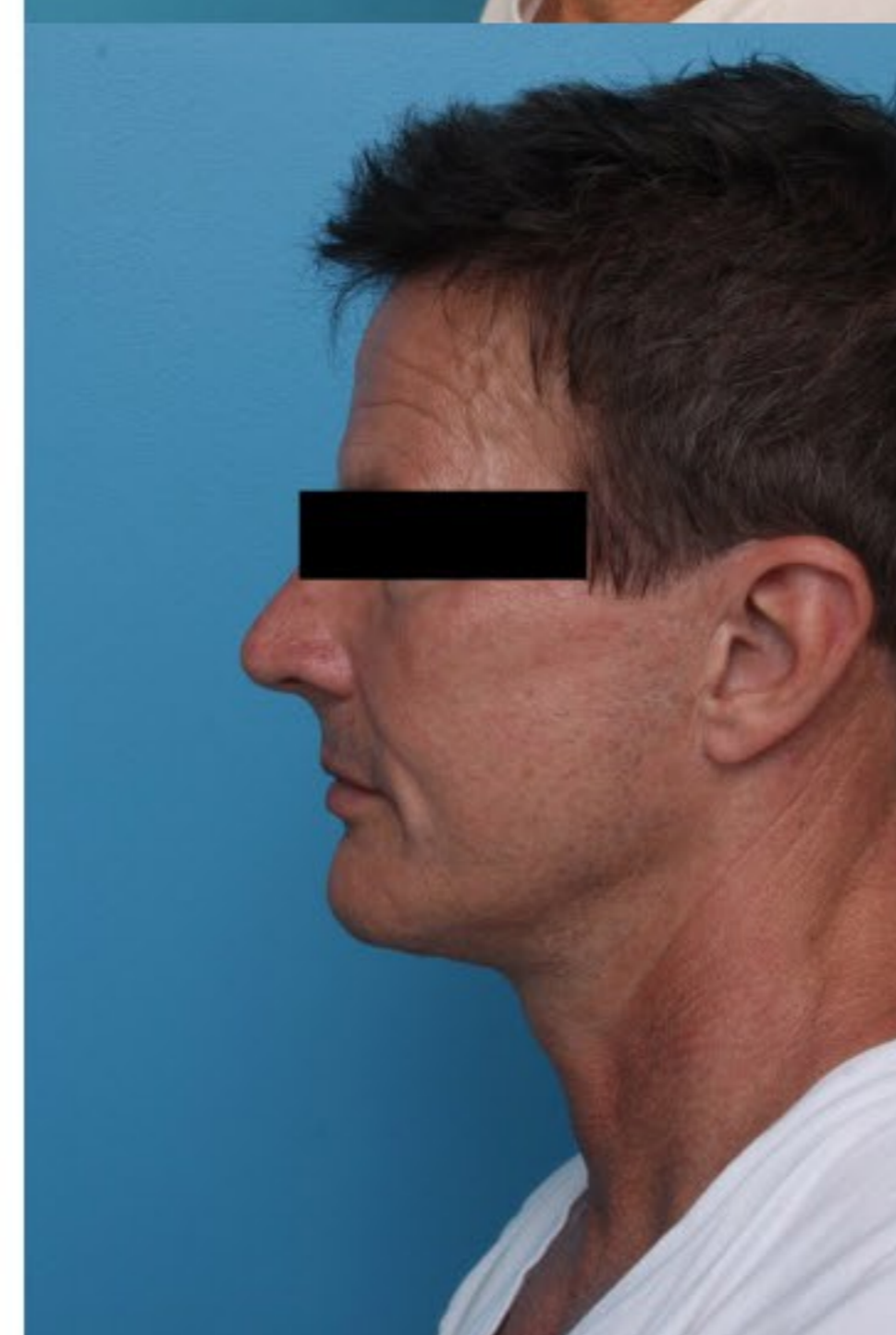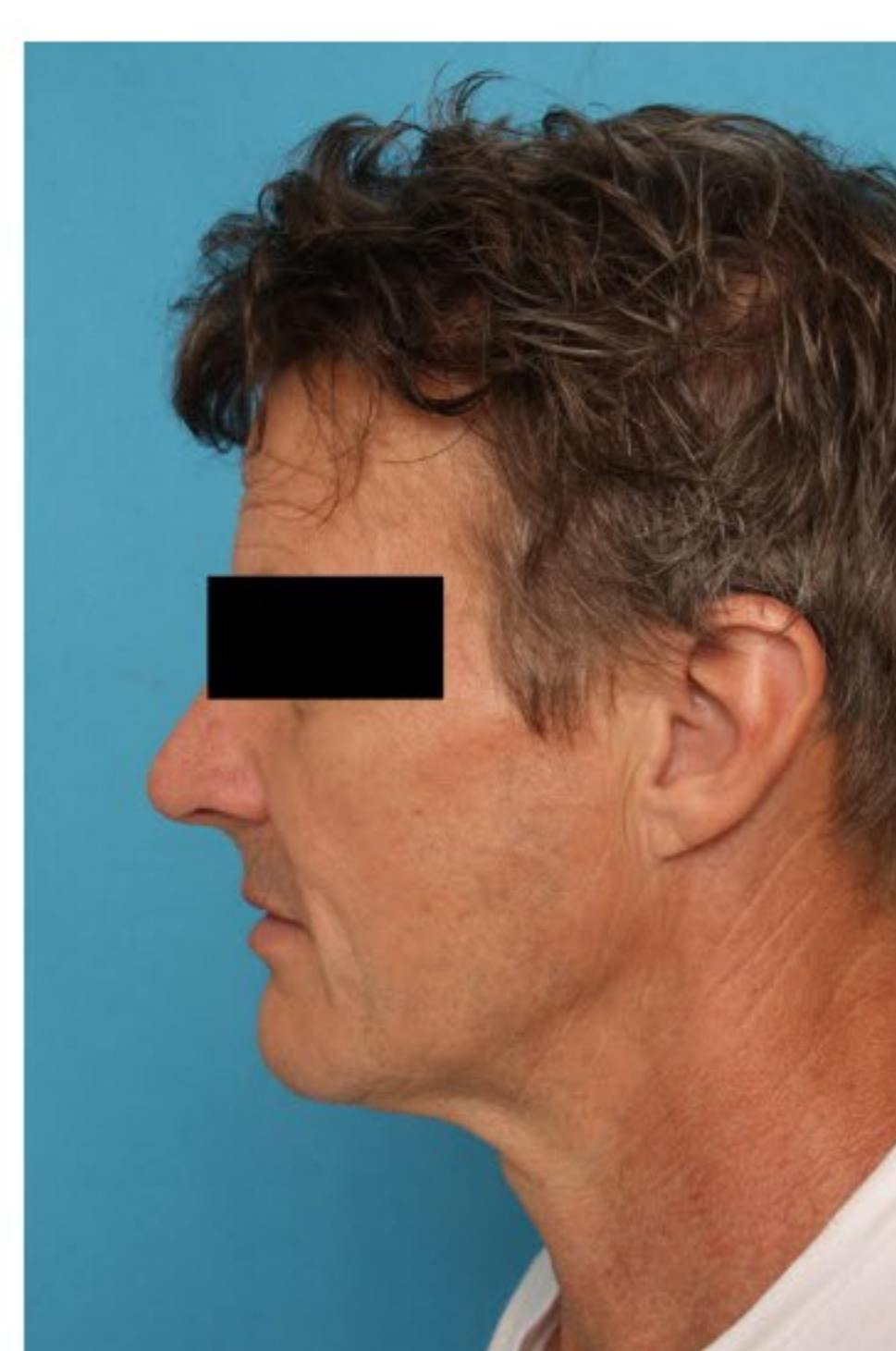1 2 3 next › last »



45-Year-old female patient shown before (above) and four days after (below) Instalift and surgical blepharoplasty. All photos courtesy Dr. Patrick Sullivan.



This 42-year old female patient didn't like her sad appearance and wanted a lift with contouring of her face and neck. She is shown before and 1 year after an extended SMAS lift, with autologous fat injected into multiple areas to enhance the contour around the mouth, jawline, and chin.



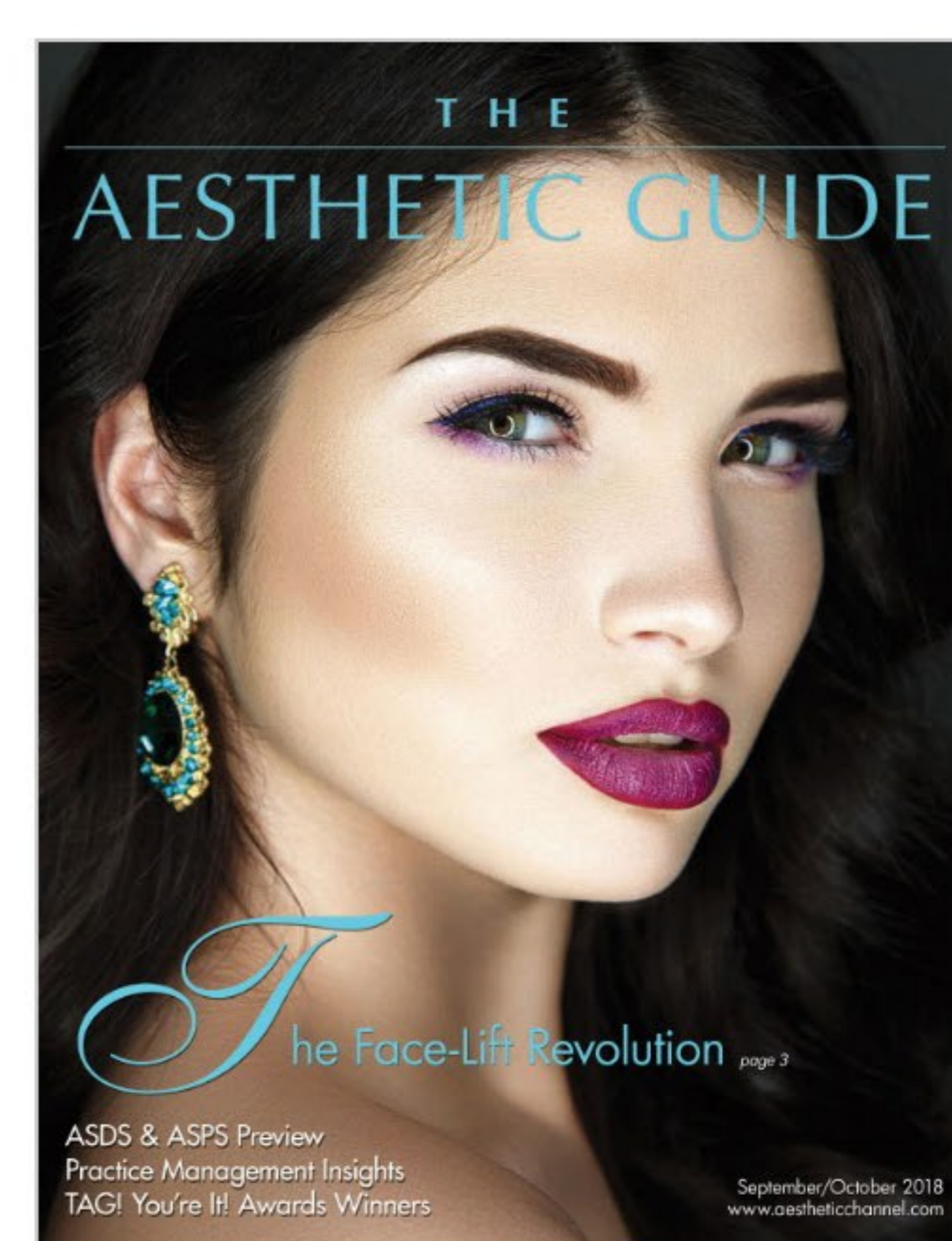
This 56-year-old male patient came in with concerns about his face and neck. He is shown before and 28 months after an extended SMAS face and neck lift with fat injections.

Resource Topics

Partner Content

- Advances in Aesthetic Technology
- Aesthetic Lasers
- Fat Reduction
- Vaginal Rejuvenation
- Wrinkle Treatments

CURRENT ISSUE



Vol 21 No 5

DIGITAL EDITION

T H E AESTHETIC CHANNEL



RELATED ARTICLES

- Improving the patient experience
- Millennium Medical Technologies refines regenerative medicine
- RF microneedling for festoon treatment
- PMMA: A Good filler with a bad rap?
- How MiXto fits into my practice